

Iatrogenic femoral arteriovenous fistula: endovascular treatment with covered stent implantation and 4-year follow-up

Barbaros E. Çil, İlkay Akmangit, Bora Peynircioğlu, Muşturay Karçaaltıncaba, Saruhan Çekirge

ABSTRACT

Puncture site complications such as arteriovenous fistula after femoral arterial catheterizations are becoming more common with the increasing number of endovascular procedures being performed by interventional radiologists and cardiologists. Covered stent placement with endovascular technique for these lesions represents an appealing treatment alternative because it is only minimally invasive and requires less hospitalization and recovery time compared to surgical repair. Herein, we present an adult patient with a post-catheterization deep femoral artery-to-femoral vein fistula, which was successfully treated with a balloon-expandable Jostent peripheral stent-graft placement. Fourth year follow-up angiography showed the covered stent to be patent.

Key words: • femoral artery • arteriovenous fistula • stents • polytetrafluoroethylene (PTFE)

Arteriovenous fistula (AVF) is described as an anomalous communication between an artery and a vein, which is frequently caused by an iatrogenic or traumatic etiology. Femoral AVFs almost always develop secondary to penetrating injuries and percutaneous vascular interventions (1).

Although surgical corrections are very common in the treatment of limb AVFs, endovascular approach has become widely popular in recent years due to the development of new endovascular techniques (2). Herein, we present the fourth-year follow-up results of a covered stent, which was placed by endovascular approach to treat an iatrogenic femoral AVF.

Case report

A 67-year-old woman was referred to our clinic after it was determined with a Doppler ultrasound examination that she had a femoral AVF. She had swelling and numbness in her right leg. Three months earlier, she underwent coronary angiography, approached from the right groin. According to the patient's history, swelling of the leg started immediately after this procedure.

Digital subtraction angiography was then repeated in our clinic, approaching from the left groin. There was an AVF between the proximal portion of the right deep femoral artery (DFA) and femoral vein (Figure 1a and b). After performing diagnostic angiography, an 8F Balkin 'cross-over' vascular sheath (William Cook Europe, Bjaeverskov, Denmark) was placed via the left main femoral artery into the right common iliac artery. Next, under road-map guidance, the distal part of the right DFA was catheterized and a 0.035 inch 260 cm stiff guide wire (Amplatz Super Stiff, Boston Scientific Corporation, Miami, FL, USA) was placed. Heparine was then administered with an initial bolus dose of 5,000 units followed by 1,000 units/hour infusion. After performing the necessary vessel diameter measurements with digital calibration, a peripheral polytetrafluoroethylene (PTFE) covered stent (Jostent Peripheral Stent Graft, Jomed GmbH, Rangendingen, Germany) between 4-9 mm in diameter and 28 mm long was manually mounted on a 6 mm x 4 cm angioplasty balloon (Powerflex P3, Cordis Europe N.V., Roden, The Netherlands). Again using road-map guidance, it was then placed across the AVF to seal the artery at the site of the fistula.

Control arteriography immediately after stent deployment confirmed the ideal position and patency of the covered stent, as well as the occluded AVF (Figure 1c).

The patient was put on clopidogrel (loading dose of 300 mg followed by 75 mg/day per orally) for 3 months and 100 mg/day acetylsalicylic acid for lifetime. Heparine infusion was stopped 24 hours after the procedure.

From the Department of Radiology (B.E.Ç. ✉ barbaros@hacettepe.edu.tr), Hacettepe University School of Medicine, Ankara, Turkey.

Received 6 April 2004; revision requested 17 May 2004; revision received 18 August 2004; accepted 15 September 2004.

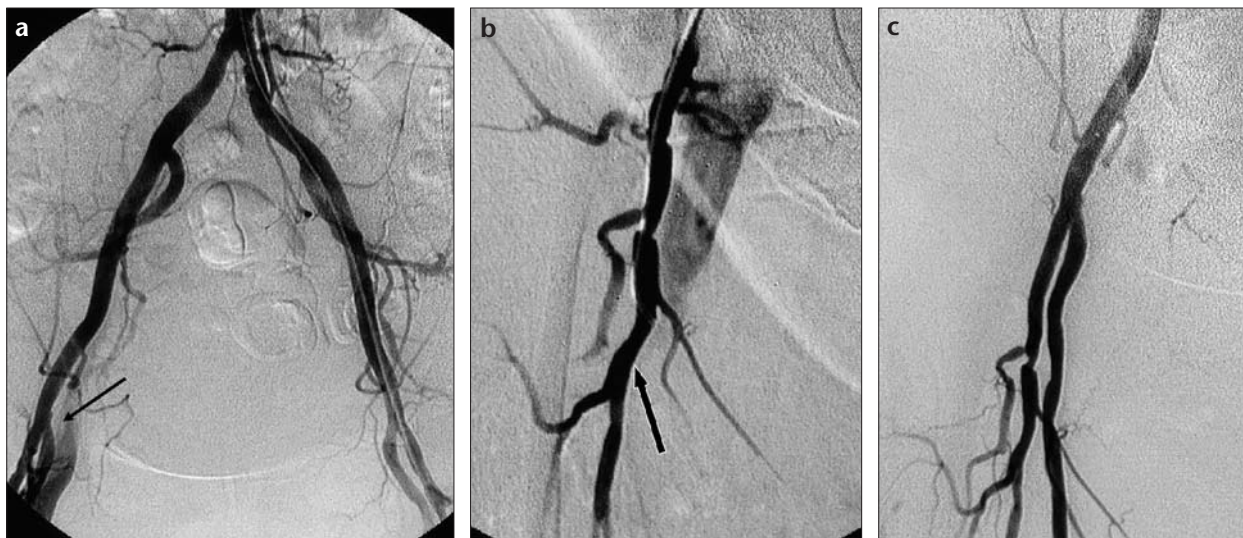


Figure 1. a-c. Pelvic digital subtraction angiography (a) reveals femoral venous filling (arrow) consistent with an AVF at the distal portion of the right femoral artery bifurcation. Selective catheterization (b) shows the right deep femoral artery as the source of the AVF (arrow). After covered stent placement (c), filling of the fistula ceased.

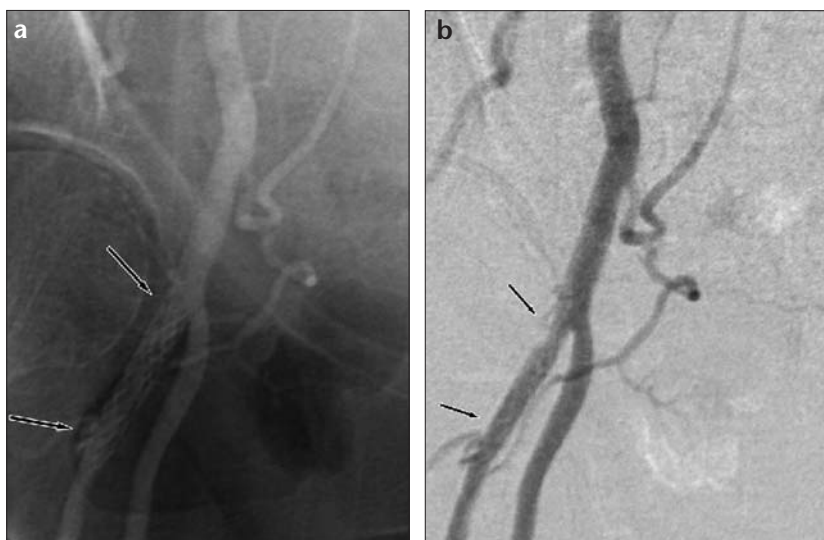


Figure 2. a, b. At the fourth-year follow-up, non-subtracted (a) and subtracted (b) digital angiography images demonstrate the patent covered stent (arrows).

At the fourth-year follow-up, the patient presented with claudication symptoms in the right leg for which she underwent an angiography. Findings were consistent with a severe atherosclerotic stenosis at the right common iliac artery and a patent covered stent at the right DFA (Figure 2). She then underwent a successful stenting of the right common iliac artery.

Discussion

Arteriovenous fistula, i. e., abnormal arteriovenous communication, usually occurs secondary to penetrating trauma such as stabbing and gun shot wounds, or is related to iatrogenic fac-

tors like surgical procedures, biopsies, angiographies, and venous catheterizations in the lower extremities.

It is rare to develop an AVF spontaneously or secondary to blunt traumas in the limbs (1). The diagnosis of an AVF in the extremities can be made with history and physical examination. In physical examinations, loud bruit in auscultation and thrill on palpation are diagnostic (3). Dilation can be seen in the artery proximal to the fistula, as well as the surrounding venous structures. Ischemia and skin ulceration can occur due to the blood steal through the fistula, and venous hypertension and bacterial endocarditis may also oc-

cur due to abnormal venous drainage (1, 3).

Although color Doppler sonography and, nowadays, CT and MR imaging play an essential role in the diagnosis of extremity AVFs, in most cases conventional angiography is still required for accurate lesion localization and tailoring of the surgical or endovascular treatment (2-4).

In treatment of extremity AVFs, surgical procedures such as partial resection, ligation, and primary repair are frequently used options (2, 5). In cases with a delayed diagnosis of an AVF, significant enlargement of the surrounding venous structures and nerve damage can potentially cause difficulties for a surgical approach in treatment (2). A simple perforation of an enlarged venous structure with high flow, which has a relatively thin wall, may lead to a massive hemorrhage during the surgery (4). Furthermore, perisurgical mortality and morbidity rates are high in patients with severe trauma and multi-system problems.

Recent improvements in endovascular techniques have created significant and effective alternatives to surgical treatment. Metallic coils and covered stent implantations have been utilized frequently for endovascular treatment of AVFs (6-9). With the significant improvement in stent technology in the last decade, utilization of covered stents for traumatic AVFs and pseudo aneurysms is becoming quite popular (2, 7, 8, 10-18). Using covered stents

for treating AVFs is technically easy and it has been reported to have a high technical success rate and a low complication rate in different series in the literature (4, 8, 12, 16, 18, 19). The one-year patency rate of covered stents in iliac, femoral, and popliteal arteries is reported to be around 83-88% in published studies (17, 18).

However, there is no accurate data regarding the long-term follow-up results of covered stents in peripheral arteries. Our case is significant because a covered stent in a medium size peripheral artery, the DFA, has remained patent through the fourth-year follow-up. The literature contains several studies pointing out similar restenosis rates in covered and bare stents (19). However, the subacute occlusion rate is relatively higher with covered stents as compared to bare stents, and therefore clopidogrel as an antiaggregating medication should be administered for at least 3 months after the procedure (19). Accordingly, we kept our patient on clopidogrel for 3 months. Additionally, several experimental studies revealed that a covered stent could be more thrombogenic in comparison to a bare metallic stent (20). The reason for this was reported to be late onset endothelialization. Especially in small caliber vessels, polyethylene tetraphthalate (PAT) covered stents (e.g. Wallgraft, Boston Scientific, USA) were found to be more thrombogenic and immunogenic as compared to polytetrafluoroethylene (PTFE) covered stents (20, 21). Additionally, in peripheral stents, several complications may be seen including compression, deformation, and crushing. Although we do not have any long-term comparative studies available at this point, an endovascular approach, with its minimally invasive

nature, and short and relatively painless recovery period, appears to be a significant and effective alternative to surgical treatment. Furthermore, as innovations in stent technology evolve, there will probably be more flexible, longer, and less thrombogenic and immunogenic stents available in the near future. Consequently, the success rate and efficacy of endovascular treatment of peripheral AVFs and pseudoaneurysms shall rise.

References

1. Straton CS, Tisnado J. Spontaneous arteriovenous fistulae of the lower extremities: angiographic demonstration in five patients with peripheral vascular disease. *Cardiovasc Intervent Radiol* 2000; 23:318-321.
2. Beregi JP, Prat A, Willoteaux S, Vasseur MA, Boularand V, Desmoucelle F. Covered stents in the treatment of peripheral arterial aneurysms: procedural results and midterm follow-up. *Cardiovasc Intervent Radiol* 1999; 22:13-19.
3. Stigall KE, Dorsey JS. Late complications of traumatic arteriovenous fistula. Case report and overview. *Am Surg* 1989; 55:180-183.
4. Parodi JC, Schonholz C, Ferreira LM, Bergan J. Endovascular stent-graft treatment of traumatic arterial lesions. *Ann Vasc Surg* 1999; 13:121-129.
5. Graham AJ, Barros D'Sa AAB. Missed arteriovenous fistulae and false aneurysms in penetrating lower limb trauma: relearning old lessons. *Injury* 1991; 22:179-182.
6. Katz MD, Hanks SE. Arteriography and transcatheter treatment of extremity trauma. In: Baum S, Pentecost MJ, eds. *Abrahams' Angiography*, Vol III. Philadelphia: Little, Brown and Company, 1997; 3:857-867.
7. Cragg AH, Lund G, Rysavy JA, Salomonowitz E, Castaneda-Zuniga WR, Amplatz K. Percutaneous arterial grafting. *Radiology* 1984; 150:45-49.
8. Marin ML, Veith FJ, Panetta TF, et al. Percutaneous transfemoral insertion of a stented graft to repair a traumatic femoral arteriovenous fistula. *J Vasc Surg* 1993; 18:299-302.

9. Marin ML, Veith J, Panetta TF, et al. Transfemoral endoluminal stented graft repair of a popliteal artery aneurysm. *J Vasc Surg* 1994; 19:754-757.
10. Parodi JC. Endoluminal stent grafts: an overview. *J Invasive Cardiol* 1997; 9:227-229.
11. Marin ML, Veith FJ, Cynamon J, et al. Transfemoral endoluminal repair of a penetrating vascular injury. *J Vasc Intervent Radiol* 1994; 5:592-594.
12. Baltacioglu F, Cimsit NC, Cil B, Cekirge S, Ispir S. Endovascular stent-graft applications in iatrogenic vascular injuries. *Cardiovasc Intervent Radiol* 2003; 26:434-439.
13. Rousseau H, Gieskes L, Joffre F, et al. Percutaneous treatment of peripheral aneurysms with the Cragg EndoPro System. *J Vasc Interv Radiol* 1996; 7:35-39.
14. Cardon JM, Cardon A, Joyeux A, Vidal V, Noblet D. Endovascular repair of iliac artery aneurysm with endoprosthesis I: a multicentric French study. *J Cardiovasc Surg (Torino)* 1996; 37 Suppl 1:45-50.
15. Criado E, Marston WA, Ligush J, Mauro MA, Keagy BA. Endovascular repair of peripheral aneurysms, pseudoaneurysms, and arteriovenous fistulas. *Ann Vasc Surg* 1997; 11:256-263.
16. Marin ML, Veith FJ, Panetta TF, et al. Transfemoral endoluminal stented graft repair of a popliteal artery aneurysm. *J Vasc Surg* 1994; 19:754-757.
17. Henry M, Amor M, Henry I, et al. Percutaneous endovascular treatment of peripheral aneurysms. *J Cardiovasc Surg (Torino)* 2000; 41:871-883.
18. Thalhammer C, Kirchherr AS, Uhlich F, Waigand J, Gross CM. Postcatheterization pseudoaneurysms and arteriovenous fistulas: repair with percutaneous implantation of endovascular covered stents. *Radiology* 2000; 214:127-131.
19. Sovik E, Klow NE, Brekke M, Stavnes S. Elective placement of covered stents in native coronary arteries. *Acta Radiol* 2003; 44:294-301.
20. Dolmatch BL, Dong YH, Trerotola SO, Hunter DW, Brennecke LH, LaBounty R. Tissue response to covered Wallstents. *J Vasc Interv Radiol* 1998; 9:471-478.
21. Hussain FM, Kopchok G, Heilbron M, Daskalakis T, Donayre C, White RA. Wallgraft endoprosthesis: initial canine evaluation. *Am Surg* 1998; 64:1002-1006.